



Balloon-occluded middle adrenal artery embolization and percutaneous microwave ablation of a metastatic adrenal tumor from renal cell carcinoma

Steven D. Kao 
Siddharth A. Padia 
John M. Moriarty 
Ravi N. Srinivasa 

ABSTRACT

Renal cell carcinomas present with locally advanced or metastatic disease in 25% of patients. Thermal ablation may be considered in selected patients with single-site or oligometastatic disease. In the study, we describe single-session transarterial particle embolization with the assistance of a balloon-occlusion catheter and microwave ablation of a large hypervascular adrenal metastasis using cone-beam computed tomography and fluoroscopic XperGuide needle guidance.

Renal cell carcinomas (RCC) represent 80%-85% of primary renal neoplasms and present with locally advanced or metastatic disease in 25% of patients.¹ In patients with advanced or metastatic clear cell RCC, systemic therapy is the mainstay of treatment.¹ Surgical metastasectomy and thermal ablation may be considered in selected patients with single-site or oligometastatic disease during or after targeted systemic therapy, particularly for refractory tumors.¹ This report describes techniques and outcomes for a patient undergoing embolization and ablation of a large RCC metastasis.

Institutional review board approval was not required for this report. A 59-year-old man with a history of stage 2 clear cell RCC status post total nephrectomy 13 years prior presented with cough, underwent computed tomography (CT) of the chest, and was found to have biopsy-proven metastatic disease in mediastinal lymph nodes. Additional sub-centimeter pulmonary nodules, hyper enhancing pancreatic lesions, and bilateral adrenal masses were discovered. The patient was started on axitinib and pembrolizumab, and over an 8-month period of observation on systemic therapy, there was interval stability of all sites of metastatic disease except for a growing left adrenal mass which now measured 8.6 cm (Figure 1). Interventional radiology was consulted for minimally invasive treatment of the left adrenal metastasis.

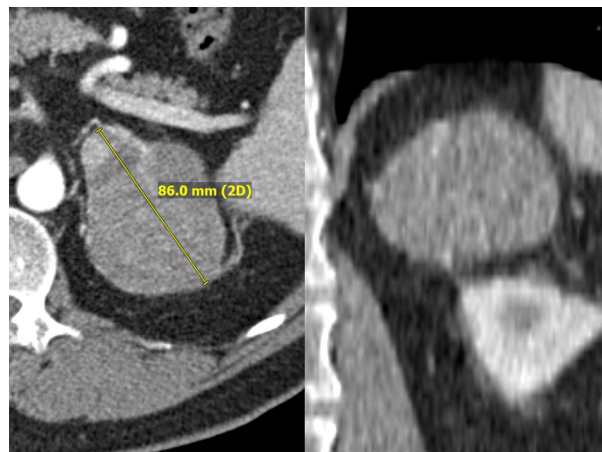

Figure 1. Axial and coronal image from pre-procedure CT scan demonstrating heterogeneously enhancing left adrenal RCC metastasis, measuring 8.6 cm. CT, computed tomography; RCC, renal cell carcinoma.

From the Division of Vascular and Interventional Radiology, Department of Radiology (S.D.K. ✉ skao@mednet.ucla.edu, S.A.P., J.M.M., R.N.S.), UCLA Medical Center, Los Angeles, California, USA.

Received 30 January 2021; revision requested 3 March 2021; last revision received 24 March 2021; accepted 9 May 2021.

Publication date: 5 October 2022.

DOI: 10.5152/dir.2022.21055

You may cite this article as: Kao SD, Padia SA, Moriarty JM, Srinivasa RN. Balloon-occluded middle adrenal artery embolization and percutaneous microwave ablation of a metastatic adrenal tumor from RCC. *Diagn Interv Radiol.* 2022;28(5):495-497.

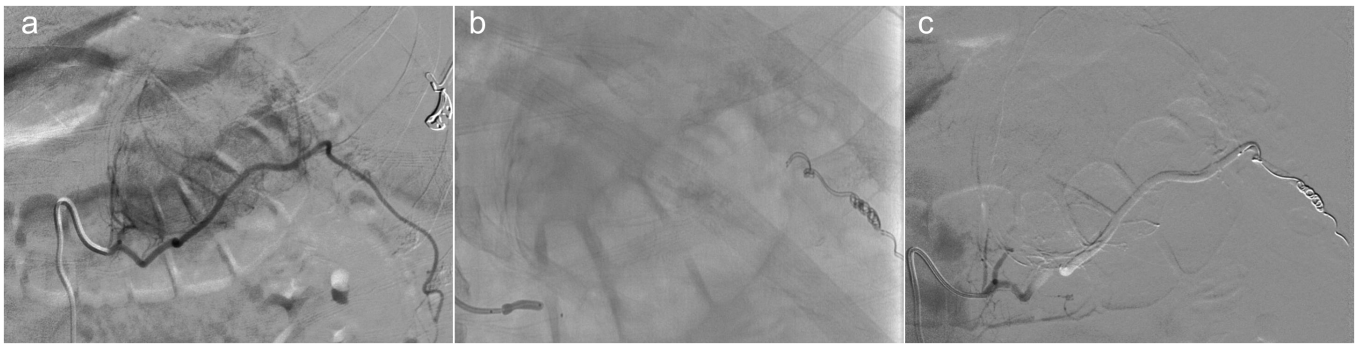


Figure 2. Balloon-occlusion catheter assisted particle embolization of left adrenal mass with distal coil protection. (a) Selective angiogram of the left adrenal artery demonstrating supply to hypervascular mass and distal supply. (b) Spot fluoroscopic image demonstrating position of balloon-occlusion catheter during embolization. (c) Post particle embolization angiogram demonstrating complete devascularization and embolic solution stasis.

Technique

Given the hypervascular nature of RCC metastases and the large size of this tumor, we elected to perform embolization immediately prior to microwave ablation to reduce bleeding during ablation. The patient was placed under general anesthesia and femoral arterial access was obtained. Although hypertensive urgency has been described with ablation of adrenal masses, given that the metastasis had replaced much of the native adrenal gland and that we would be embolizing the gland prior to ablation, we elected to defer alpha-blockade and rather allow anesthesia staff to treat blood pressure changes as needed. Aortography demonstrated a dominant left middle adrenal artery (MAA) supplying the left adrenal mass. This was selected using a 5 Fr MIK catheter (Cook Medical) and selective angiography demonstrated perfusion of the entire left adrenal mass and distal perfusion of perirenal fat (Figure 2). A Renegade HI-FLO microcatheter and Fathom-16 guidewire (Boston Scientific) were used to access the left MAA distal to the branches supplying the adrenal mass, and coil embolization was performed using detachable microcoils (Boston Scientific) to protect the distal soft tissues. Repeat angiography

of the left MAA demonstrated exclusion of the artery distal to the mass and slowed flow in the arterial segment supplying the mass. Embolization to complete stasis was then performed using 1/6th of a vial of 100-300 μ m Embosphere (Merit Medical) and one-third of a vial of 100 μ m Embozene (Varian Medical Systems) particles. A 4 \times 10 mm Scepter C balloon-occlusion catheter (MicroVention) was deployed in the proximal left MAA during embolization. Post-embolization angiography demonstrated complete devascularization of the left adrenal mass. Catheters and sheaths were removed and arteriotomy was sealed with an Angio-Seal VIP closure device (Terumo Corporation).

The patient was then placed in prone position. Non-contrast cone-beam CT was performed at the level of the left adrenal mass. XperCT and XperGuide needle guidance software was used to plan and

overlay the trajectory of the ablation probes (Philips Healthcare). Under fluoroscopic guidance with XperGuide overlays, 1 PR-20 and 2 PR-15 microwave ablation probes (NeuWave Medical) were placed in the left adrenal mass (Figure 3). Ablation was then performed for 8 minutes at 65 W. The ablation probes were then withdrawn by 4 cm and a second round of ablation was performed for 8 minutes at 65 W to target the posterior portion of the mass. Although blood pressures and heart rate transiently rose to 157/80 and 80 from 110/60 mmHg and 70 beats per minute, respectively, for approximately 3 minutes at the start of ablation, the blood pressure normalized with a bolus of propofol. Post-procedural follow-up CTs of 1, 3, and 5 months demonstrated expected post-ablation changes of the left adrenal mass without residual or recurrent tumor (Figure 4). Additional sites of disease were stable.

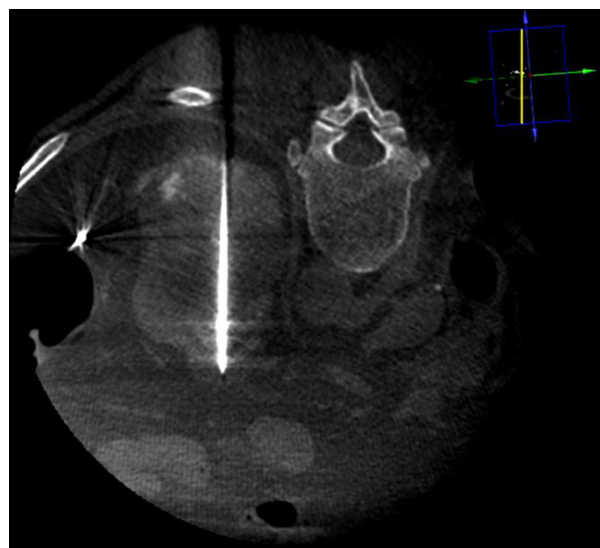


Figure 3. Cone-beam CT and fluoroscopic-guided microwave ablation. Microwave ablation probes were inserted under fluoroscopy with XperGuide overlays. The probe was advanced another 1 cm prior to ablation.

Main points

- Interventional treatment options for hypervascular metastases include direct percutaneous ablation and transarterial embolization.
- Single-session transarterial particle embolization and microwave ablation using cone-beam computed tomography and fluoroscopic XperGuide needle guidance may be considered for patients with hypervascular metastases.

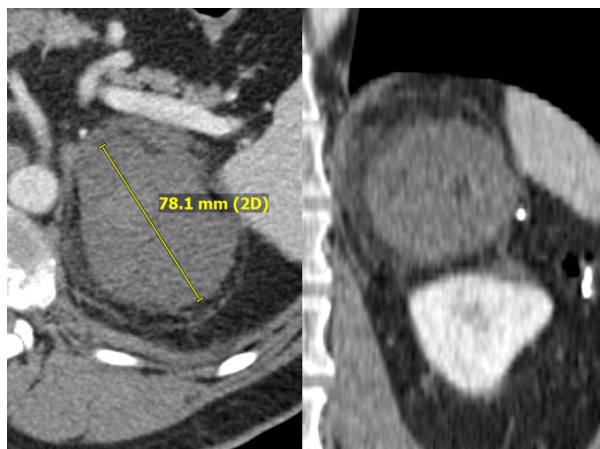

Figure 4. Axial and coronal image from 9-month post-procedure CT scan demonstrating left adrenal RCC metastasis without residual enhancement, now measuring 7.8 cm.

Discussion

Treatment of adrenal metastases historically involved surgical resection and was generally limited to selected patients with oligometastatic disease.¹ However, case series of image-guided ablation for small adrenal metastases have shown comparable outcomes to surgical resection, with high rates of technical success and primary treatment efficacy, low rates of tumor recurrence and few grade 3/4 complications per common terminology criteria for adverse events.^{2,3} However, rates of tumor progression with ablative technologies are often suboptimal for larger tumors.⁴ Percutaneous radiofrequency ablation combined with renal artery embolization (RAE) in renal tumors has demonstrated high local tumor control, metastasis-free survival, cancer-specific survival, and overall survival rates.⁵ Similarly, combination therapy with chemoembolization and ablation has been shown to improve local control rates and overall survival in hepatic tumors with diameters greater than 3 cm and hepatocellular carcinoma (HCC) metastatic to the adrenal glands.^{6,7} In

this case, we opted to embolize with bead embolic due to its relative ease of delivery through narrow lumen microcatheters. Embolization with lipiodol or n-butyl cyanoacrylate is also feasible but may be technically challenging due to the viscosity of the embolic material. In cases where there are feeding branch arteries near the origin and slow distal flow, with concern for reflux of embolic into the aorta, a balloon-occlusion catheter may be used to increase safety and maximize the amount of embolic delivered. Although additional studies are needed to clarify the role of interventional therapy in adrenal metastases, combination embolization and ablation can potentially aid in achieving improved local tumor control in lesions with larger diameters.

Conflict of interest disclosure

The authors declared no conflicts of interest.

Funding

Steven D. Kao has received consultation fees from Philips Healthcare. Ravi N. Srinivasa is a consultant for Boston Scientific and

Teleflex Medical. Siddharth Padia is a consultant for Boston Scientific, and Bristol Meyers Squibb has received a research grant from Varian Medical Systems. John Moriarty is a consultant for Argon Medical, Angiodynamics Inc, Boston Scientific, Inari Medical, Penumbra, BD Bard, Thrombolex and Pavmed Inc.

References

- Garnick MB. Primary neoplasms of the kidney. In: Brady HR, Wilcox CS, eds. *Therapy in Nephrology and Hypertension: A Companion to Brenner and Rector's the Kidney*. Philadelphia: WB Saunders; 1998.
- Zhou K, Pan J, Yang N, et al. Effectiveness and safety of CT-guided percutaneous radiofrequency ablation of adrenal metastases. *Br J Radiol*. 2018;91(1085):20170607. [\[CrossRef\]](#)
- Hasegawa T, Yamakado K, Nakatsuka A, et al. Unresectable adrenal metastases: clinical outcomes of radiofrequency ablation. *Radiology*. 2015;277(2):584-593. [\[CrossRef\]](#)
- Winokur RS, Pua BB, Madoff DC. Role of combined embolization and ablation in management of renal masses. *Semin Intervent Radiol*. 2014;31(1):82-85. [\[CrossRef\]](#)
- Sommer CM, Pallwein-Prettner L, Vollherbst DF, et al. Transarterial embolization (TAE) as add-on to percutaneous radiofrequency ablation (RFA) for the treatment of renal tumors: review of the literature, overview of state-of-the-art embolization materials and further perspective of advanced image-guided tumor ablation. *Eur J Radiol*. 2017;86:143-162. [\[CrossRef\]](#)
- Yuan H, Liu F, Li X, Guan Y, Wang M. Clinical efficacy of chemoembolization with simultaneous radiofrequency ablation for treatment of adrenal metastases from hepatocellular carcinoma. *Cancer Imaging*. 2018;18(1):24. [\[CrossRef\]](#)
- Yamakado K, Anai H, Takaki H, et al. Adrenal metastasis from hepatocellular carcinoma: radiofrequency ablation combined with adrenal arterial chemoembolization in six patients. *AJR Am J Roentgenol*. 2009;192(6):W300-W305. [\[CrossRef\]](#)